

canine JOINT THERAPY

with Synovetin OA™ breaks the inflammatory cycle associated with synovitis

Steven M. Fox, MS, DVM, MBA, PhD
Senior Veterinary Consultant

John M. Donecker, VMD, MS
Exubriion Therapeutics, Inc.

DEFINITIONS

Note: First usages of terms defined in the glossary are indicated by **bold type**.

autoradiography: Images produced by decay emissions from a radionuclide.

beta particle: A high-energy electron emitted from the nucleus of a radioactive atom; beta particles typically have a wide tissue penetration range of 0.05–12.00 mm that diminishes over distance, making uniform dosing difficult and possibly necessitating shielding during transport and handling.

colloid: A mixture of insoluble microparticles that remain distributed in solution without precipitating or settling to the bottom; nontoxic colloids are used therapeutically to bind radionuclides to prevent them from escaping the intra-articular space into systemic distribution.

conversion electron: A low-energy electron released from an atomic shell as a result of radioactive decay, resulting when gamma radiation emitted by the nucleus is transferred to the electron; conversion electrons are monoenergetic in contrast to beta particles.

degenerative joint disease (DJD): The inclusive term for joint disease with end-stage arthritides such as osteoarthritis (OA), characterized by a pathogenesis that often begins with joint injury due to trauma or conformational abnormalities, followed by inflammation, deterioration of articular cartilage and underlying bone, loss of joint space, and arthritic remodeling accompanied by pain and functional loss.

hormesis: The biological phenomenon whereby a beneficial effect results from exposure to low doses of an agent that is otherwise toxic or lethal when given at higher doses; in the case of radiation hormesis, low doses of ionizing radiation, within the range of and just above natural background levels, are beneficial, stimulating the activation of repair mechanisms that protect against disease that are not activated in absence of ionizing radiation.

ionizing radiation: Radiation that results from freeing subatomic particles such as electrons, neutrons, or beta particles from atoms or compounds, thus ionizing the original source material.

radionuclide: An unstable isotope of an atom that emits radiation released from the atomic nucleus. Some radionuclides exist naturally, but those with research and therapeutic applications are usually produced artificially; a radioisotope.

radiosynoviorthesis (RSO): Also known as radiosynovectomy (RSV), RSO refers to injection into the synovial space of a low-energy radioisotope to treat joint inflammation and mitigate chondromalacia. The goal of RSO is reduction of pain and synovial hypertrophy by exerting a therapeutic effect at the site of a tissue lesion or injury with minimal or no radiation exposure to healthy surrounding tissue.

synoviorthesis: A medical therapy using intra-articular injection of a compound that diminishes the degree of synovial hypertrophy, thereby mitigating pain and the development of inflammation and arthritis; can be performed by chemical synoviorthesis or radiosynoviorthesis, with the latter being preferred when a suitable radionuclide is available.

tin-117m (Sn-117m): An artificially produced radionuclide of tin with medical applications for localized treatment and imaging. Tin-117m has a half-life of 14 days. Two principal forms of the energy that it emits are (1) conversion electrons that have a short penetration range in tissue (~0.3 mm), and (2) imageable gamma radiation, which enables monitoring of local distribution in tissue. Tin-117m is metastable, indicated by the “m” suffix, meaning that it is a radioisotope with an energetic nucleus and a relatively long half-life and therefore distinct from highly unstable radionuclides with shorter half-lives.

KEY POINTS

- A growing body of evidence indicates that synovitis is the initial, pre-radiographic event in the progression of degenerative joint disease (DJD).
- Synovitis initiates expression of pro-inflammatory mediators such as cytokines, chemokines, growth factors, and proteinases that activate macrophage infiltration leading to cartilage degradation.
- Early therapeutic intervention to treat synovitis prior to the onset of osteoarthritis (OA) can prevent, delay, or limit the extent of arthritic changes.
- Synovetin OA™, a homogeneous colloid of the novel radionuclide tin-117m, is a device for intra-articular administration to treat synovial inflammation and mitigate OA as the end stage of DJD in dogs.
- Tin-117m has a short, well-defined tissue penetration range and a half-life of 14 days, enabling precise application and a duration of effect sufficient to achieve apoptosis and ablation of inflammatory cells in the synovium.
- Synovetin OA™ affects the hyperplastic stage of synovitis and generally helps to improve the synovium toward normalcy.
- A University of Missouri study confirmed that Synovetin OA™ injected into canine elbow joints was phagocytized by inflammatory macrophages without adversely affecting adjacent synoviocytes (synoviocyte B cells) or causing histopathological changes in articular cartilage, bone, or connective tissue.
- The targeted therapeutic effect of Synovetin OA™ differs from NSAIDs, piprants, and corticosteroids, avoiding the prostaglandin-related side effects associated with these therapies.

In primary care practice, following the diagnosis of canine **degenerative joint disease (DJD)**, including osteoarthritis (OA), the diagnosis is confirmed by radiographic changes in the joint, followed by conservative therapy with nutraceuticals, NSAIDs, or corticosteroids, and weight control in dogs that are overweight or obese. Piprants, prostaglandin receptor antagonists (PRAs) recognized by the World Health Organization in 2013 as a new class of analgesic drugs, offer an additional option for first-line DJD analgesic therapy.¹ Surgery and regenerative medicine may be appropriate for more advanced cases where those interventions might be indicated. A growing body of evidence validates that synovitis is a pre-radiographic event in DJD and that early therapeutic intervention to treat synovitis prior to the clinical onset of OA can prevent, delay, or limit the extent of arthritic changes.^{2,3} This report presents how **synoviorthesis** with Synovetin OA™, a novel **radionuclide** designed for intra-articular administration, can effectively treat synovial inflammation and help mitigate OA as the end stage of DJD. The ability to treat OA disease without affecting the homeostasis-regulating effects of cyclooxygenase (COX) represents a different mode of action with therapeutic, analgesic, and safety benefits and is an alternative to long-term use of COX-selective NSAIDs and piprants.




THE ROLE OF SYNOVITIS in disease progression

Synoviocytes are metabolically highly active cells directly involved in joint homeostasis as well as the pathophysiology of DJD.² Although synovitis tends to be more severe in advanced OA, it is clearly present from the earliest stages of DJD progression.⁴ Clinical signs include joint swelling due to synovial hyperplasia or synovial fluid effusion, a sudden increase in pain, and transient morning stiffness.² Recent studies have convincingly shown that diffuse synovitis precedes the development of radiographic OA, both in human and canine hosts.^{2,4-7} In a controlled study, women with effusive synovitis detected by MRI (n=133) 1 year before onset of radiographic OA of the knee and at a baseline 4 years before onset were, respectively, 3.23 and 4.6 times more likely to develop radiographic OA compared to matched controls (n=133) who did not develop OA during the study period.⁵ Similarly, the Multicenter Osteoarthritis (MOST) study found that subjects (n=53) with MRI-detected effusion synovitis (grade ≥ 2 , range 0–3) of the knee at baseline had a 2.7-fold greater risk ($p=0.002$) of cartilage loss 30 months later compared to individuals without synovitis.⁷

Cranial cruciate ligament (CCL) deficiency and rupture, the most common cause of hindlimb lameness in dogs,^{6,8} is a particularly relevant disease model for evaluating the incidence of pre-radiographic and DJD-associated synovitis. Veterinary investigators at Purdue University evaluated the synovial macrophage density in the affected stifle joint of dogs with naturally occurring cranial cruciate ligament (CCL) rupture (n=17) and in 5 healthy control dogs. Macrophage density was increased in all affected joints and was significantly associated with radiographic severity of OA and with presence of the pro-inflammatory cytokines interleukin-6 (IL-6) and tumor necrosis factor- α .⁹ In a European study, CCL mechanical strength was significantly reduced in lab animal models with immune-mediated synovitis, and IL-8 expression was higher in canine CCLs that ruptured during the subsequent 6 months.¹⁰ University of Wisconsin investigators found that arthroscopic evidence of synovitis was significantly correlated with radiographic OA ($p<0.05$) and significantly increased ($p<0.05$) in dogs with CCL rupture (n=16) compared to stable contralateral stifles and control dogs with intact CCLs (n=10).¹¹ Not only was synovitis present in all CCL joints that ruptured, but it was present to some degree in all stable contralateral stifles and was significantly more severe than synovitis in the normal stifles of control dogs. CCL fiber disruption was detected in 75% of stable contralateral stifle joints and was significantly correlated ($p<0.05$) with severity of synovitis. These observations indicate that synovitis is an early feature of CCL arthropathy in dogs before the development of clinical joint instability and that synovitis severity is correlated with radiographic OA in joints of dogs with minimal or no clinically detectable CCL damage.

Investigators have defined various inflammatory pathways whereby acute or chronic synovitis leads to DJD structural damage.^{6,10,12} In the case of canine CCL deficiency, studies have shown that the impaired ligament releases collagen type I, its principal component.¹⁰ Synovial macrophages are activated and proceed to phagocytize collagen type I antigens. Collagen type I antigen presentation in synovial tissue stimulates a cascade of pro-inflammatory proteinases and cytokines. The proteinases further damage the CCL and induce cartilage degradation.^{3,10,12} Pro-inflammatory cytokines such as IL-1, IL-6, IL-8, and TNF- α signal the recruitment of inflammatory cells, stimulate enzymes that cause cartilage loss, and induce proliferation of synovial cells and fibroblasts responsible for synovial hyperplasia and joint fibrosis. Significantly, expression of pro-inflammatory cytokines has been found to increase in dogs prior to CCL rupture occurring during the subsequent 6 months.¹⁰ This indicates that synovitis initiates biochemical processes that can result in ligament deficiency even before onset of clinical disease.

Inflammatory mediators secreted by macrophages in synovitis have also been shown to stimulate increased vascular turnover leading to synovial and osteochondral angiogenesis, or the growth of new capillaries from pre-existing vasculature.^{2,4,13,14} Neovascularization at the subchondral junction leads to edema, inflammatory cell infiltration, ossification, and osteophyte formation, as well as joint damage that perpetuates the cycle of inflammation.¹³ Bony processes formed at the joint margin become innervated, exacerbating pain through structural reorganization of the joint.¹³



THE 'SPONGE ANALOGY'

of joint maintenance and pathophysiology

Articular cartilage is avascular and aneural, maintaining homeostasis by diffusion of synovial fluid into cartilage matrix by normal joint loading and unloading. This enables chondrocytes to assimilate nutrients and evacuate catabolic waste resulting from matrix degradation. The process is analogous to the movement of water into and out of a sponge while being squeezed repeatedly in a basin of water. The sponge analogy of joint maintenance also applies to the pathophysiology of DJD. The synovial lining of the joint capsule, normally one to two cells thick, is responsible for

production of hyaluronan but also produces degradative enzymes, cytokines, and other inflammatory mediators in response to a biomechanical or infectious etiology. Enzymes expressed by the synovium into the synovial fluid are assimilated into cartilage as a result of sponge-like diffusion, inducing bony pathology and structural changes over time. This process leads to release of inflammatory mediators from chondrocytes in a self-sustaining catabolic cycle. Concurrently, prostaglandins that mediate inflammation activate subsynovial nociceptors to induce a pain response.¹⁵

RADIOSYNOVIORTHESIS for treatment of synovitis

Clinical but pre-radiographic synovitis is diagnosed by MRI or ultrasound, or more typically in veterinary medicine, by arthroscopy (Figure 1). Front-line therapies to treat synovitis in order to prevent or delay chronic arthritic changes include systemic NSAIDs, glucocorticoids, and local joint therapies such as corticosteroid and hyaluronic acid injections. As an alternative to these traditional therapies, **radio•synovi•orthesis (RSO)** has a long history of successful use in human medicine, particularly in Europe, where it is an accepted form of outpatient therapy for treatment of rheumatoid arthritis, psoriatic arthritis, and OA.¹⁶⁻¹⁹ Also known as brachytherapy (the terminology often used in reference to local or contact radiotherapy to treat tumors as well as joint disease), RSO refers to the use of low-energy **ionizing radiation** emitted by a radionuclide for joint therapy. The ionizing radiation penetrates the synovial membrane, where it dissipates to achieve apoptosis and ablation of inflamed cells.

As a localized, intra-articular treatment, RSO avoids several problems associated with systemic therapies, such as toxicity resulting from chronic use of NSAIDs or immunosuppressive drugs and tissue degradation that can occur from overuse of intra-articular corticosteroids. Characteristically, 64% of NSAID adverse drug events in dogs are gastrointestinal, 21% are renal, and 14% are hepatic.²⁰ In human medicine, RSO has a favorable cost-benefit ratio, particularly when compared to surgery; a low rate of side effects; and application to virtually all articular joints, especially small, peripheral joints such as the finger joints.¹⁷ In patients that either respond poorly or have

adverse side effects following traditional therapies, RSO is a useful option that is now being applied in veterinary medicine.

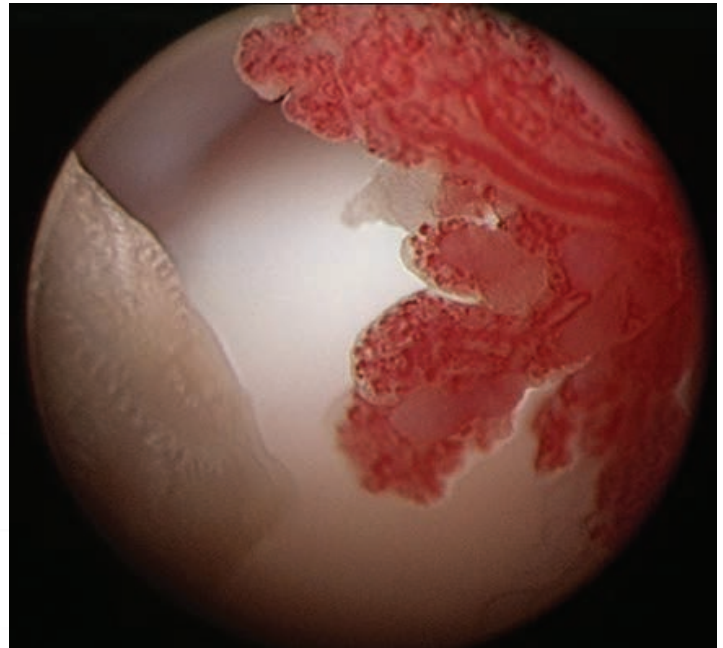


Figure 1. The red mass at right shown in an arthroscopic view of a canine diarthroidal joint with early-onset degenerative joint disease (DJD) reveals robust synovitis and synovial hyperplasia, the initial event in the histopathology of DJD, occurring before the onset of radiographic changes. *Photo, S. M. Fox, Chronic Pain in Small Animal Medicine, used with permission*

synovetin OA™: a novel radionuclide

Synovetin OA™ is a homogeneous **colloid** of **tin-117m**, a unique radionuclide developed for use as an RSO agent. Synovetin OA™ is indicated for intra-articular administration to treat synovial inflammation caused by OA. Tin-117m is a novel radionuclide with important advantages over earlier therapeutic radioisotopes used in clinical medicine. Three radionuclides have been widely used in human medical practice: yttrium-90, rhenium-186, and erbium-169. As these three radionuclides decay, they emit radiation in the form of **beta particles**, relatively high-energy electrons with a wide range of soft-tissue penetration up to 11.0 mm, which diminishes with distance. The variable tissue penetration of beta particles risks irradiation of adjacent non-target tissue. Yttrium-90 and rhenium-186 have a relatively short half-life, 2.7 and 3.7 days respectively, which creates logistical limitations that may result in inconsistent delivery of sufficient radiation to the target site.²¹

In contrast to high-energy beta radiation, tin-117m emits abundant **conversion electrons**, low-energy particles with a short, relatively non-diminishing penetration range of approximately 0.3 mm. Tin-117m has a half-life of nearly 14 days, providing an ideal duration of effect spanning several half-lives in order to achieve therapeutic results and enable short-term stability during storage and handling. The short, well-defined tissue penetration range of tin-117m conversion electrons enables precise dosimetry and avoidance of adverse effects on non-target tissues that can occur with beta-emitting radionuclides. No other radionuclide has the properties of tin-117m, making it particularly well suited for RSO in dogs.

In addition to conversion electrons, tin-117m emits gamma radiation, a zero-mass quantum of light and electromagnetic radiation that results from nuclear decay of a radionuclide. Gamma radiation is non-therapeutic, but readily detectable in tissue by imaging methods such as scintigraphy and radiography. By emitting gamma radiation at 159 kilo-electron volts (keV), tin-117m can be used diagnostically to detect the distribution and duration of its presence in tissue

of treated patients. This application is similar to that for technetium-99m, a widely used systemic radionuclide with gamma emissions of 140 keV that is used in diagnostic procedures, including evaluation of bone structure and function. The gamma emission component of tin-117m provides an objective basis for diagnostic monitoring, disease staging, dosage estimates, and assessing response to therapy.^{22,23}

Synovetin OA™ is a patented preparation of tin-117m developed specifically for RSO and other potential applications in veterinary and human medicine. Synovetin OA™ embeds tin-117m in a homogeneous colloid.^{24,25} The radionuclide particles are small enough to be phagocytized by synovial macrophages, but large enough to avoid leakage outside the joint. In situ retention of the homogeneous tin colloid in laboratory animals has been measured out to 5 half-lives (i.e., 70 days), a duration sufficient for therapeutic effectiveness. Synovetin OA™ has demonstrated safety and effectiveness following RSO of experimental OA in rats and elbow joints of client-owned pet dogs (Figure 2). Successful RSO in relatively small canine joints is noteworthy given the commonplace occurrence of canine elbow and stifle dysplasia with associated OA: types of small-joint pathology that have historically been difficult to treat surgically.^{6,26}

Figure 2.

Intra-articular injection of Synovetin OA™ into the caudolateral aspect of a canine elbow, positioned at 45-degree flexion, between the lateral condyle of the humerus and the triceps tendon. Following injection, the joint is put through a range of motion to disperse the radiocolloid throughout the synovial surface.

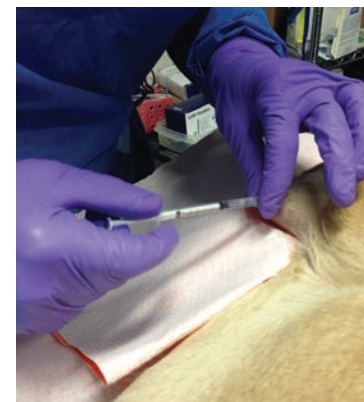

Photo courtesy of Cynthia Doerr, MD

synovetin OA™: mode of action

Use of low-energy ionizing radiation is the basis of radiation **hormesis** (low dose: beneficial response), the removal of damaged cells by apoptosis followed by normal cell replacement in response to subnecrosis-inducing irradiation.²⁷ The proposed mode of action of Synovetin OA™ is the absorption of the tin-117m colloid by macrophages involved in the inflammatory process. The limited tin-117m emission

penetration depth of 0.3 mm provides a clinical effect without extending beyond the synovium to non-target tissue. The 14-day half-life enables in situ retention that is long enough to provide both a practical shelf life and produce a therapeutic response that breaks the inflammatory cycle initiated by pre-radiographic synovitis.

PROOF OF CONCEPT:

Autoradiography and histopathology of canine elbow joints injected with Synovetin OA™

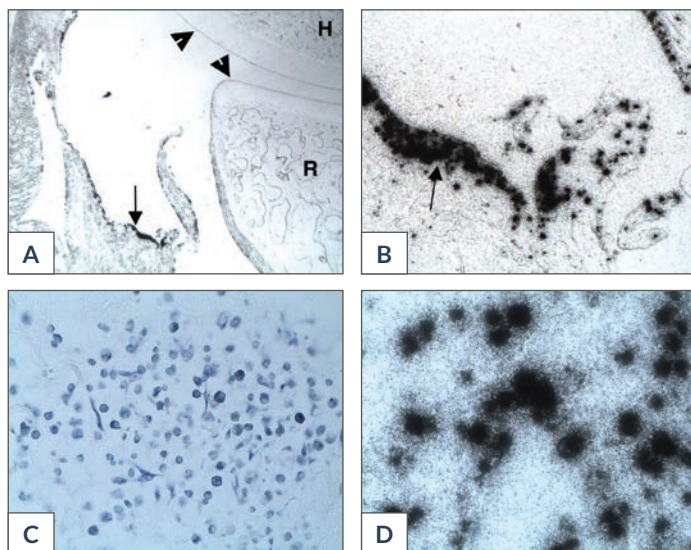
A laboratory study was conducted at the University of Missouri School of Veterinary Medicine to determine the distribution of Synovetin OA™ in synovium following injection into canine elbow joints (n=5 dogs) and whether treatment-related histopathology occurred in synovial or adjacent non-synovial tissue. **Autoradiography** of tissue sections obtained 47–49 days after treatment determined the extent of colloidal distribution within the synovium and in subsynovial tissues, articular cartilage, and bone samples. A board-certified veterinary pathologist evaluated tissue sections for histopathologic lesions following necropsy of these study dogs.

No microscopic histopathologic changes or autoradiographic evidence of Synovetin OA™ assimilation were observed in articular cartilage, bone, or connective tissue, confirming that homogeneous tin-117m colloid did not produce changes in

non-target tissues. Three of 5 elbow sections had autoradiographic images indicating mild or minimal focal synovial or subsynovial colloid-containing macrophage infiltration in naturally occurring areas of inflammation adjacent to the anterior surface of the distal humerus (Figure 3). Non-inflamed areas of the synovium showed either small foci or no inclusion of Synovetin OA™.

The histopathology and autoradiography results validated that naturally occurring synovitis in the canine joint occurs prior to the onset of radiographic changes to the cartilage and bone (Figure 3A). Results also demonstrated that macrophages at sites of naturally occurring synovial inflammation phagocytize homogeneous tin-117m colloid particles in Synovetin OA™, where they remain in situ and exert a therapeutic effect (Figure 3D).

Figure 3. A: Autoradiograph of dog no. 2 shows normal articular cartilage (arrowheads) of the canine humerus (H) and proximal radius (R) and concurrent presence of tin-117m colloid particles (arrow) in macrophages in an inflamed area of the synovial lining of a canine elbow joint, 16x. B: Autoradiograph of the synovium and sub-synovium of dog no. 2 showing uptake of tin-117m colloid by macrophages adjacent to the radius (arrow), 100x. C: Histopathology slide showing inflammatory cells from synovium of canine elbow joint from dog no. 1. D: Autoradiograph of dog no. 1 shows tin-117m colloid particles assimilated by macrophages below the synovial surface, 400x. The presence of normal articular cartilage concurrently with autoradiographic evidence of pro-inflammatory macrophages indicates that (1) synovitis occurs prior to onset of arthritic changes, and (2) intra-articular synoviorthesis with a homogeneous tin-117m colloid (Synovetin OA™) results in selective uptake of a therapeutic radionuclide by inflammatory cells at the target site.



DISCUSSION

Synovitis is a pre-radiographic event that progresses to OA as the clinical endpoint. This pathophysiological sequence suggests that DJD should not be thought of as a single entity, but as a continuum of events following joint (organ) insult.²⁸ Thus, the synovium, rather than osteophytes and cartilage, as well as pre-arthritis pain management, should be the focus of early intervention in DJD. The demonstration that synovitis is predictive of structural changes in the progression of DJD suggests that early intervention targeting synovial inflammation may have disease-modifying effects.^{2,3} RSO using Synovetin OA™ offers significant advantages over conventional high-energy, beta-emitting radionuclides with a wide tissue penetration range that makes precise dosimetry difficult. The limited but non-diminishing tissue penetration range of conversion electrons emitted by Synovetin OA™ avoids exposure of non-target tissue. In addition, the 14-day half-life of tin-117m is sufficiently long to ensure a therapeutic effect over several half-lives, and the homogeneous tin-117m colloid enables in situ retention within the joint, where it is assimilated by inflammatory cells in the synovium. Ninety-nine percent dose retention one week after intra-articular injection of lab animals with Synovetin OA™ has been demonstrated.²⁹ No other radionuclide with the properties of tin-117m exists.²⁵

Traditional, first-line DJD therapies such as NSAIDs and oral corticosteroids, as well as the novel piprant PRAs, can mitigate pain and inflammation.¹ However, these agents are not considered disease modifying, and they are non-targeted in the sense that they affect the host systemically. Current guidelines recommend avoiding NSAID co-therapy with other agents in that drug class,³⁰ and the first-in-class PRA grapiprant tablets are contraindicated for concurrent use with COX-inhibiting NSAIDs or corticosteroids.³¹ In contrast, clinical studies showed Synovetin OA™ as a co-therapy with NSAIDs, corticosteroids, or nutraceuticals. In this respect, Synovetin OA™ conforms to current pain management guidelines recommending a multimodal strategy that blocks

multiple pain pathways.³⁰ This approach potentially enables lower doses and reduces the likelihood of side effects associated with any single drug. The use of RSO as an acute therapy may further minimize the possibility for adverse effects associated with overuse, such as what can occur with excessive use of intra-articular corticosteroids.

Importantly, RSO targets the synovium, the initial site of DJD-associated joint inflammation. As such, it is free of the inherent side effects associated with systemic NSAID therapy and may be NSAID-sparing. An effective, mechanism-based, targeted DJD therapy such as RSO administered early in disease progression has the potential for routine use in DJD treatment. It may be particularly well suited for high-value working dogs at increased risk of DJD, such as those used in livestock farming, police, military, and drug-enforcement roles.



ACKNOWLEDGEMENTS

The authors acknowledge the contribution of Mark Dana of Scientific Communication Services, LLC, in the preparation of this report.

References

1. Rausch-Derra L, Huebner M, Wofford J, et al. A prospective, randomized, masked, placebo-controlled multisite clinical study of grapiprant, an EP4 prostaglandin receptor antagonist (PRA), in dogs with osteoarthritis. *J Vet Intern Med.* 2016;doi: 10.1111/jvim.13948.
2. Sellam J, Berenbaum F. The role of synovitis in pathophysiology and clinical symptoms of osteoarthritis. *Nat Rev Rheumatol.* 2010;6:625-635.
3. Scanzello CR, Umoh E, Pessler F, et al. Local cytokine profiles in knee osteoarthritis: elevated synovial fluid interleukin-15 differentiates early from end-stage disease. *Osteoarthritis Cartilage.* 2009;17:1040-1048.
4. Wenham CY, Conaghan PG. The role of synovitis in osteoarthritis. *Ther Adv Musculoskel Dis.* 2010;2:349-359.
5. Atukorala I, Kwok CK, Guermazi A, et al. Synovitis in knee osteoarthritis: a precursor of disease? *Ann Rheum Dis.* 2016;75:390-395.
6. Griffon DJ. A review of the pathogenesis of canine cranial cruciate ligament disease as a basis for future preventive strategies. *Vet Surg.* 2010;39:399-409.
7. Roemer FW, Guermazi A, Felson DT, et al. Presence of MRI-detected joint effusion and synovitis increases the risk of cartilage loss in knees without osteoarthritis at 30-month follow-up: the MOST study. *Ann Rheum Dis.* 2011;70:1804-1809.
8. Comerford EJ, Smith K, Hayashi K. Update on the aetiopathogenesis of canine cranial cruciate ligament disease. *Vet Comp Orthop Traumatol.* 2011;24(2):91-98. doi: 10.3415/VCOT-10-04-0055.
9. Klocke NW, Snyder PW, Widmer WR, et al. Detection of synovial macrophages in the joint capsule of dogs with naturally occurring rupture of the cranial cruciate ligament. *Am J Vet Res.* 2005;66:493-499.
10. Doom M, de Bruin T, de Rooster H, van Bree H, et al. Immunopathological mechanisms in dogs with rupture of the cranial cruciate ligament. *Vet Immunol Immunopathol.* 2008;125:143-161.
11. Bleedorn JA, Greuel EN, Manley PA, et al. Synovitis in dogs with stable stifle joints and incipient cranial cruciate ligament rupture: a cross-sectional study. *Vet Surg.* 2011;40:531-543.
12. Hayashi K, Manley PA, Muir P. Cranial cruciate ligament pathophysiology in dogs with cruciate disease: A review. *J Am Anim Hosp Assoc.* 2004;40:385-390.
13. Bonnet CS, Walsh DA. Osteoarthritis, angiogenesis and inflammation. *Rheumatology.* 2005;44:7-16.
14. Walsh DA, Bonnet CS, Turner EL, et al. Angiogenesis in the synovium and at the osteochondral junction in osteoarthritis. *Osteoarthritis Cartilage.* 2007;15:743-751.
15. Fox SM. Pathophysiology of osteoarthritic pain. In: *Chronic Pain in Small Animal Medicine.* CRC Press: Boca Raton, Florida; 2009;74-96.
16. Kampen WU, Voth M, Pinkert J, et al. Therapeutic status of radiosynoviorthesis of the knee with yttrium [⁹⁰Y] colloid in rheumatoid arthritis and related indications. *Rheumatology.* 2007;46:16-24.
17. Karavida N, Notopoulos A. Radiation synovectomy: an effective alternative treatment for inflamed small joints. *Hippokratia.* 2010;14:22-27.
18. Klett R, Lange U, Haas H, et al. Radiosynoviorthesis of medium-sized joints with rhenium-186-sulfide colloid: a review of the literature. *Rheumatology.* 2007;46:1531-1537.
19. Modder G. Rheumatoid and related joint diseases. In: *Radiosynoviorthesis. Involvement of Nuclear Medicine in Rheumatology and Orthopaedics.* Meckenheim, Germany: Warlich Druck Verlagsges, MbH; 1995;13-23.
20. Fox SM. *Multimodal Management of Canine Osteoarthritis*, 2nd ed. CRC Press: Boca Raton, Florida; 2016:45.
21. Silva M, Luck JV Jr, Llinas A. Chronic hemophilic synovitis: The role of radiosynovectomy. *Treatment Hemophilia.* 2004;33:1-10.
22. Srivastava SC, Atkins HL, Krishnamurthy GT, et al. Treatment of metastatic bone pain with tin-117m Stannic diethylenetriaminepentaacetic acid: a phase I/II clinical study. *Clin Cancer Res.* 1998;4:61-68.
23. Srivastava SC. The role of electron-emitting radiopharmaceuticals in the palliative treatment of metastatic bone pain and for radiosynovectomy: applications of conversion electron emitter Tin-117m. *Brazilian Arch Biol Technol.* 2007;50:49-62.
24. Doerr C, Stevenson N, Gonzales G, et al. Homogeneous Sn-117m colloid radiosynovectomy results in rat models of joint disease. *J Nucl Med.* 2015;suppl 3:1243.
25. Stevenson NR, St. George G, Simon J, et al. Methods of producing high specific activity Sn-117m with commercial cyclotrons. *J Radioanal Nucl Chem.* 2015;305:99-108.
26. Kunst CM, Pease AP, Nelson NC, et al. Computed tomographic identification of dysplasia and progression of osteoarthritis in dog elbows previously assigned OFA grades 0 and 1. *Vet Radiol Ultrasound.* 2014;55:511-520.
27. Feinendegen LE, Pollycove M, Sondhaus CA. Responses to low doses of ionizing radiation in biological systems. *Nonlinearity Biol Toxicol Med.* 2004;2:143-171.
28. Sokolove J, Lepus CM. Role of inflammation in the pathogenesis of osteoarthritis: latest findings and interpretations. *Ther Adv Musculoskel Dis.* 2013;5:77-94.
29. Stevenson N, Lattimer J, Selting K, et al. Abstract S6-03: Homogeneous Sn-117m colloid—A novel radiosynovectomy agent. *World J Nucl Med.* 2015;14(Suppl 1):S15-S68.
30. Epstein M, Rodan I, Griffenhagen G, et al. 2015 AAHA/AAFP Pain Management Guidelines for Dogs and Cats. *J Am Anim Hosp Assoc.* 2015;51:67-84.
31. Food and Drug Administration. Galliprant—a nonsteroidal anti-inflammatory drug (NSAID) for dogs with osteoarthritis. Available at <https://www.fda.gov/animal-veterinary/animal-health-literacy/galliprant-nonsteroidal-anti-inflammatory-drug-nsaid-dogs-osteoarthritis>. Accessed August 29, 2019.